

**MEDIAL COLLATERAL LIGAMENT REPAIR FOLLOWING COMPLETE LIGAMENT TRANSECTION: AN EXPERIMENTAL STUDY IN RABBITS**

**E.Carmeli<sup>1</sup>, Y.Beer<sup>2</sup>, N.Halperin<sup>1</sup>, R.Coleman<sup>3</sup>, D.Robinson<sup>1,5</sup>, T.Brosh<sup>4</sup>, Z.Nevo<sup>5</sup>**

*<sup>1</sup>Dept. of Physical Therapy, Sackler Faculty of Medicine, The Stanley Steyer School of Health Professions, Tel Aviv University, Ramat Aviv, Israel; <sup>2</sup>Dept. of Orthopaedics, Assaf Harofeh Medical Center, Zerifin, Israel; <sup>3</sup>Dept. of Anatomy and Cell Biology, Technion-Institute of Technology, Haifa, Israel; <sup>4</sup>Laboratory of Orthodontics, Goldschleger School of Dental Medicine, Tel Aviv University, Ramat Aviv, Israel; <sup>5</sup>Dept. of Clinical Biochemistry, Sackler School of Medicine, Tel Aviv University, Ramat Aviv, Israel*

**Abstract.** The purpose of this study was to evaluate the repair processes of the medial collateral (MCL), lateral collateral (LCL), anterior cruciate (ACL) and posterior cruciate (PCL) ligaments after complete dislocation by arthrotomy, and after disconnection. Forty eight mature young male white New Zealand rabbits. All four ligaments were reconnected using non-absorbable sutures, without limb immobilization. The contralateral knees served as internal controls. The effectiveness of Diclofenac (Voltaren, an NSAID), hyaluronic acid, and hyaluronic acid combined with collagenase in the healing processes was examined. 12 non-operated rabbits (control group) received intraarticular injections of 1 ml 0.9% saline 3 per week for 3 weeks; 12 rabbits received intramuscular (Glutei) injections of Diclofenac sodium 1% (1ml/1kg BW) 3 per week for 3 weeks; 12 rabbits received intraarticular injections with 1 ml hyaluronic acid alone; 12 rabbits received intraarticular injections of hyaluronic acid and collagenase. Biomechanical and histological examinations of the joints were performed. The results indicated that healing of ACL and PCL was not achieved in any group. A favorable response to Diclofenac treatment was noticed in MCL as determined by both histology and biomechanical testing. In conclusions, Diclofenac administered by injections may offer some clinical benefits following major knee operations or injury.  
*(Biol.Sport 21:379-391, 2004)*

---

Reprint request to: Dr. Carmeli Eli, Physical Therapy Dept.,  
Sackler Faculty of Medicine, Tel Aviv University, Ramat Aviv 69978, Israel  
Tel: +972 36405434; Fax: +972 3 6405436; E mail: elie@post.tau.



*Key words:* Knee - Ligament - Treatment

## **Introduction**

The two intraarticular ligaments (anterior cruciate and posterior cruciate) and the two periarticular ligaments (medial and lateral collateral) are important mechanical elements contributing to the complex functioning and stability of the knee joint. The ligaments are composed of various densities and spatial arrangements of collagen fibers embedded in a protein-polysaccharide matrix, commonly referred to as ground substance. Ligament injuries are common consequences of sports accidents, vehicle crashes, terrorist activities, wars and other traumatic events [13]. Ligament damage following traumatic events or surgical treatment, commonly results in scar tissue formation and adhesions, which impede normal functioning. Ligaments are important subjects in the new field of regenerative medicine [16].

Ligament healing is of great interest to most orthopaedic surgeons. Repair and recovery from injury to ligaments is a relatively slow process compared with healing in other connective tissues [4]. The healing capacity of ligaments is very variable and dependent on multiple local physical and biological factors including biomechanical loading, biochemistry, blood supply, nutrition and growth factors. Spontaneous regeneration of damaged ligaments is very limited, and certain conditions must be met before any healing can occur. The torn ligament fibers must be confined within well-vascularized and non-infected soft tissue surroundings, and fairly precise functional and biomechanical stresses are necessary to stimulate the healing process.

We speculated that use of various chemical agents and drugs (collagenase, hyaluronic acid, Diclofenac) could possibly be effective in improving repair processes in injured ligament tissues. Collagenase is an enzyme that acts on collagen and contributes to cell membrane integrity, tissue remodeling and accelerating the repair processes. It belongs to the matrix metalloproteinases (MMPs) family of enzymes, that function in the extracellular space. Diclofenac sodium (1% Voltaren) is a non-steroid anti-inflammatory drug (NSAID) widely used to combat inflammatory processes in joints by blocking prostaglandin E (PGE<sub>2</sub>) production, and by increasing local blood flow and vascular permeability [9,10,14,15]. Hyaluronic acid (HA) is an important component of both cartilage matrix and synovial fluid, and contributes to the viscoelastic mechanical and biophysical properties of ligaments [2,21].



We undertook an experimental study on knee joints of experimental rabbits after surgical resection of the joint ligaments and reattachment to determine the effectiveness of administration of Diclofenac, hyaluronic acid, and hyaluronic acid combined with collagenase (as combined drugs to accelerate the healing) in improving repair processes in ligaments after acute injury.

### Materials and Methods

*Animals:* Forty eight male white New Zealand rabbits (8 months old), weighing  $3.5 \text{ kg} \pm 0.5$  (mean  $\pm$ SD), were operated on under sterile conditions following general anaesthesia induced by an intramuscular injection of ketamine. The right knee of each rabbit was completely dislocated in two stages. Firstly, an anterior skin incision was made to expose the two periarticular ligaments (MCL, LCL), which were disconnected in the mid-portion, and then the two intraarticular ligaments (ACL, PCL) were transected by medial parapatellar arthrotomy. The capsule was left intact. The ligaments were surgically reconnected using non-absorbable sutures and all wounds were closed routinely. The animals were allowed to move freely in their cages ( $50 \text{ cm}^2$  area) with unrestricted weight-bearing movement as tolerated. The rabbits were divided into 4 equal experimental groups. Group 1 rabbits ( $n=12$ ) were non-operated controls that received an intraarticular injection of 1 ml 0.9% saline, three times a week for 3 weeks. Group 2 rabbits ( $n=12$ ) received intramuscular (Glutei) injections of Diclofenac sodium 1% (Voltaren) 1mg/kg body weight. Group 3 rabbits ( $n=12$ ) received intraarticular injections of 1 ml 2% hyaluronic acid (BTG Inc, Weizmann Technology Park, Rehovot, Israel). Group 4 rabbits ( $n=12$ ) received a combination dose of hyaluronic acid mixed with collagenase (1 mg; Sigma C7926 type F). The mechanism which the injected substances were completely absorbed both intra and extra articular is described by Dunham *et al.*, 1993 [7]. Injection schedules were identical for all four groups and were started the first day following surgery. From previous models no changes were observed in the contralateral legs, therefore it served as internal controls [5].

3 weeks post-operation 50% of the rabbits from each group ( $n=6$ ) were sacrificed. The physical and macroscopic appearance of all the operated knees was examined and recorded and the whole knee joints prepared for histology. Eight weeks post-operation the remaining rabbits were sacrificed in order to investigate longer-term biomechanical changes in the ligaments.

The experimental protocol received approval from the Ethics Committee for animal experimentation of Tel Aviv University.



*Histology:* All operated knee joints were dissected and fixed by immersion in 4% neutral buffered formaldehyde. Following decalcification with EDTA the samples were dehydrated in graded alcohols and embedded in paraffin wax (Paraplast Plus, Oxford Labware, St.Louis, MO). 7 $\mu$ m sections from mid portion of the ligaments were stained with hematoxylin and eosin (H&E), and Masson's trichrome [22].

*Biomechanical tests:* Disarticulation of both hip and ankle joints was performed on treated and contralateral non-treated legs. Hindlimbs were individually wrapped in saline-soaked gauze, placed in plastic bags and stored at  $-20^{\circ}\text{C}$ . Prior to biomechanical testing, the specimens were stored overnight at  $4^{\circ}\text{C}$ . A Kirschner wire was attached to the trochanteric zone of the proximal end of the femur and a similar procedure was performed at the distal end of the tibia. Each specimen was attached to a materials testing machine (Instron System, series 1026, GB, SATEC, Grove City, PA, USA). The system was calibrated to a maximum load of 5kN (500 kg/1100lbs) and 1mm elongation for 5 cycles and then loaded to failure at a rate of 5mm/min [18]. We measured the uniaxial longitudinal tensile resistance of the soft tissue in the knee joint, which was recorded on-line to a personal computer and printed out graphically. Data were calculated using a Microsoft Windows Excel program. For tensile testing up to 10 kg loading capacity was applied followed by a slow release to zero resistance. Immediately after concluding the tensile testing, all soft tissues in the knee area (capsule, ligaments and tendons) were removed apart from the MCL. Tensile testing was resumed along the longitudinal direction of the MCL. The linearity and accuracy of the system is 0.5%. The residual deformation (in mm) of the ligaments was calculated by the following formula:  $X1 - X2 = \Delta\Delta X$  (X1 is 10 kg resistance, and X2 is ligament contraction). The ligament stiffness (in kg/mm) was evaluated by "force-elongation ratio" and was graphically described, and calculated by the following formula:  $\text{stiffness} = \Delta F / \Delta D$ . The slope of primary/toe and secondary/linear regions was determined (initial  $\Delta F / \Delta D$ , and linear  $\Delta F / \Delta D$ , respectively).

### Statistics

Two-way analysis of variance was used to indirectly assess postoperative healing and structural properties (stiffness and failure load) of the MCL. Paired and unpaired *t* tests were used to compare the differences in the properties between the contralateral (control) and experimental knees. The level of significance was set at  $P < 0.05$ .



## Results

Table 1 shows the profile of the experimental study groups and the procedures undertaken.

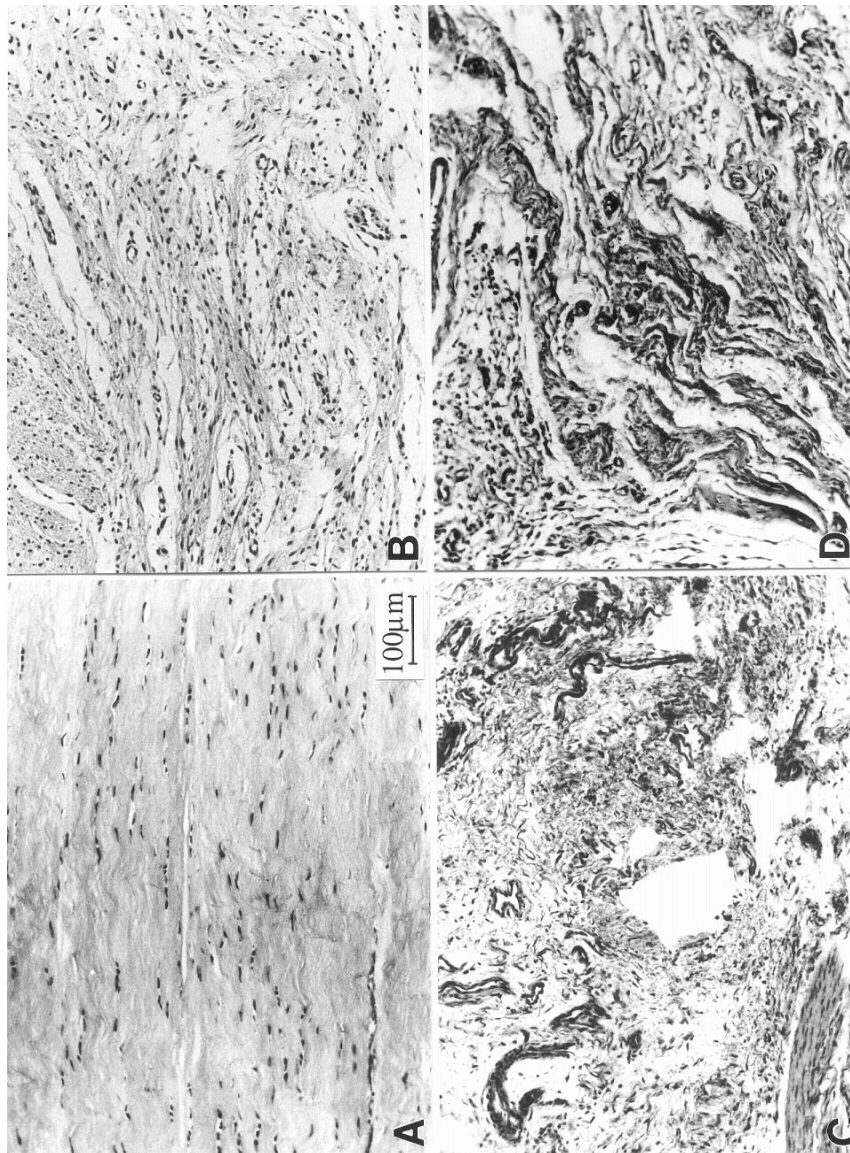
**Table 1**  
Study groups

Study groups	Rabbits (n=48)	Age (months)	Body weight (kg)
Group 1: Saline controls	12	3.87±0.57	3.60±0.34
Group 2: Diclofenac (Voltaren)	12	3.68±0.53	3.58±0.25
Group 3: Hyaluronic acid	12	3.62±0.42	3.48±0.43
Group 4: Hyaluronic acid + collagenase	12	3.71±0.49	3.57±0.33

Macroscopic observation of all operated knees at 21 days post-operation revealed no significant changes, and all ligaments appeared non-infected, white and well-defined. The intraarticular ligaments (ACL, PCL) showed no signs of repair. The healing sites remained enlarged and the gap remained discontinuous. In contrast, the extraarticular ligaments, and in particular the MCL, showed some signs of repair. The MCLs had become rounder and slightly swollen, with synovial covering visible on their surfaces.

Histological studies (Fig. 1) showed that only limited healing processes were occurring in the MCL at 3 weeks post-operation, with the appearance of new blood vessels and collagen fibers. The collagen fibers were loosely packed, disorganized and disoriented without the regular alignment along lines of force as seen in the non-treated controls. In the Diclofenac-treated rabbits (group 2) the fibers were somewhat better organized (Fig. 1B) in comparison with the other treated groups (Figs. 1C, D) though still disorganized compared with the non-operated controls (Fig. 1A).



**Fig. 1**

Histology of MCL three weeks post-operation (Masson's Trichrome staining)

**A**, Control non-operated group (Group 1); **B**, Diclofenac-treated group (Group 2); **C**, Hyaluronic acid-treated (Group 3); **D**, Hyaluronic acid + collagenase combined treatment (Group 4); All to same magnification

**Table 2**

Residual deformation of medial collateral ligament (mean values in mm  $\pm$ SD) determined using the Instron System

	Group 1 Saline control (n=12)	Group 2 Diclofenac (Voltaren) (n=12)	Group 3 Hyaluronic acid (n=12)	Group 4 Hyaluronic acid + collagenase (n=12)
contralateral/ treated knee	0.2 $\pm$ 0.089 0.2 $\pm$ 0.063	0.57 $\pm$ 0.152 0.57 $\pm$ 0.170	0.62 $\pm$ 0.109 0.15 $\pm$ 0.052	1.15 $\pm$ 0.207 0.25 $\pm$ 0.119
Students t-test *	NS	NS	P<0.0001	P<0.0001
Students t-test **	----	P<0.003#	P=0.1	P=0.1

\*Comparison between contralateral (control) knee and treated knee in each group (paired two-tail test); \*\*Comparison between treated knees of groups 2-4 and control group 1 (unpaired two-tail test); # Only group 2 treated knees (Diclofenac) showed significant difference

The results of the biomechanical tests on the MCL (residual deformation, stiffness and ultimate force failure) are shown in Tables 2-4. All operated knees showed residual deformation ranging from 0.15 through 0.57mm, therefore, when the knee relaxed the ligaments did not fully return to their initial shortened length, with the exception of the Diclofenac group (Table 2). The force displacement and residual deformation of MCL were found significant (unpaired two tail, P<0.003) only in Group 2 (Diclofenac-treated) in comparison with the non-operated (contralateral) legs (Table 2). The residual deformation of operated and non-operated MCL in the Diclofenac-treated group was similar in both legs and recorded as 0.57 mm. The ligament stiffness between the initial and linear values was significant (P<0.001) in MCL of all operated knees (Table 3).



**Table 3**Stiffness of medial collateral ligament ( $\Delta F/\Delta D$  kg/mm  $\pm$ SD)

	Group 1 Saline control (non-operated)	Group 2 Diclofenac (Voltaren)	Group 3 Hyaluronic acid	Group 4 Hyaluronic acid + collagenase
$\Delta F/\Delta D$ kg/mm $\pm$ SD	(n=12)	(n=12)	(n=12)	(n=12)
Contralateral Initial values	1.60 $\pm$ 0.15 3.50 $\pm$ 0.39	0.80 $\pm$ 0.09 2.02 $\pm$ 0.28	1.62 $\pm$ 0.50 2.97 $\pm$ 0.77	1.54 $\pm$ 0.51 3.29 $\pm$ 0.72
Linear values				
Right knee Initial values	1.22 $\pm$ 0.13 2.25 $\pm$ 0.30	0.70 $\pm$ 0.12 1.53 $\pm$ 0.15	0.88 $\pm$ 0.53 1.76 $\pm$ 0.67	1.28 $\pm$ 0.54 4.80 $\pm$ 0.48
Linear values				
Students t-test *	P<0.001	P<0.002	P<0.003	P<0.001
Students t-test **	-----	P<0.001	NS	NS

\*Comparison between contralateral (control left) knee and treated knee in each group (paired two-tail test); \*\*Comparison between treated knees of groups 2-4 and control group 1 (unpaired two-tail test); NS, non-significant

The MCL in the Diclofenac group showed less stiffness than in the control group (2.02 vs 3.50 kg/mm respectively). The hyaluronic acid group showed less linear stiffness compared to the control group (2.97 and 3.50 kg/mm respectively). Biomechanical testing indicated that the mean elongations at ultimate force failure load values for MCL were greatest (paired two-tail test) in the hyaluronic acid-treated rabbits (groups 3 and 4) with the highest and most significant values found in group 4 (Table 4). The mean ultimate force failure values of MCL in the operated knees of the Diclofenac group were comparable to those of the contralateral knees. The mean ultimate force failure values of the Diclofenac group showed no significant difference between the operated knee and the contralateral knee in comparison with non-operated controls (group 1) (Table 4). Group 4, in contrast, showed significant differences in ultimate force values in comparison with the non-operated controls.



**Table 4**

Ultimate force failure test (mean values in kg  $\pm$  SD) of medial collateral ligament determined using the Instron System

	Group 1 Saline control (non-operated) (n=12)	Group 2 Diclofenac (Voltaren) (n=12)	Group 3 Hyaluronic acid (n=12)	Group 4 Hyaluronic acid + Collagenase (n=12)
contralateral/ treated knee	6.4 $\pm$ 0.44 6.4 $\pm$ 1.09	6.6 $\pm$ 0.67 6.5 $\pm$ 0.44	6.9 $\pm$ 0.65 6.7 $\pm$ 0.94	6.9 $\pm$ 1.40 5.6 $\pm$ 1.20
Students t-test *	NS	NS	P<0.02#	P<0.002#
Students t- test **				
contralateral/ treated knee	-----	NS	NS	P<0.18

\*Comparison between contralateral (control left) knee and treated knee in each group (paired two-tail test); #Significant differences were found in Groups 3 and 4 with lower values in the treated knee; \*\*Comparison between treated knees of groups 2-4 and control group 1 (unpaired two-tail test); Only group 4 showed significant difference in ultimate force failure in comparison to control group

In general, the best results of treatment on the MCL were seen in the Diclofenac group as shown both by both histology and biomechanical testing. The hyaluronic acid group also showed some improvement in biomechanical parameters, but less than those of the Diclofenac group. However this was not seen histologically.

## Discussion

In this study, we used an experimental rabbit model of a controlled severe surgical knee injury followed by surgical reconnection of the knee ligaments, in order to examine ligament recovery under various therapeutic regimes, with particular emphasis on the MCL. Surgical reconstruction is widely recommended



for severe knee injury [19,23] however, the optimal conditions for comprehensive treatment of ruptured MCL have still to be determined [17,24]. Healing of MCL after total knee dislocation injury differs from healing occurring after an isolated injury of the MCL [11,25]. In our study we examined the healing capacities of the four major knee ligaments, but focused in particular on the MCL. Previous studies have tended to investigate the regenerative capacities of the knee ligaments as a whole [6,12] or combined knee ligament injuries [7]. Regeneration of ligaments is a slow process, compared with the healing of other connective tissues such as bone and muscle.

The effects of hyaluronic acid administration on connective tissue repair, including ligaments, tendons and joint capsules, have been fairly widely investigated and documented [1,8]. In our study examining the comparative effects of Diclofenac, hyaluronic acid and hyaluronic acid combined with collagenase on the four major ligaments of the knee of experimental rabbits, we showed that there is relatively little ligament regeneration after complete transection and surgical reconnection. The rationale and the benefit for the intraarticular use of collagenase as a proteolytic enzyme in the joint previously indicated as a good treatment for increasing in chondrocyte density and enhancing joint repair [3]. The mechanical properties of MCL in hyaluronic acid-treated and the Diclofenac-treated groups improved significantly compared with the other ligaments, but only in the Diclofenac group was this seen histologically. No significant effects on other ligaments of the knee (LCL, ACL, and PCL) were detected.

It has been reported that tearing of cruciate ligaments requires surgical intervention for healing, whereas extraarticular ligaments can undergo spontaneous, but slow, healing responses [10,23,24]. The various benefits of NSAID therapy for skeletal tissues have been documented [14,15]. The known analgetic effect of Diclofenac may influenced the animals exercise pattern and thereby ligament healing. Diminished pain and inflammation promotes earlier limb mobilization and shortens time for rehabilitation. However, the question remains whether such as early healing responses compromise the mechanical strength of the ligament.

In our study, MCLs of rabbits given HA or Diclofenac exhibited greater failure load values than those of rabbits given HA with collagenase. The appropriateness of NSAID therapy for management of soft tissue injury is controversial owing to the decrease in mechanical strength. Nonetheless, the administration of HA promoted an early healing response, and later enhanced greater mechanical strength. At 8 weeks, the mechanical values of operated MCL in the HA and Diclofenac groups were comparable to those of contralateral controls. The force



displacement of a ruptured MCL treated with an NSAID is greater than in control groups, in both the short and long-term [8,20]. The higher MCL ultimate failure in the HA and Diclofenac groups at 8 weeks may have been due to the larger cross-sectional area in the transectional site as seen by histology.

The increased MCL strength in rabbits treated with HA and Diclofenac leads us to postulate, that Diclofenac has important effects in reducing the initial inflammatory responses. The use of an NSAID should be considered as the first mode of intervention secondary to soft tissue injury, followed by administration of HA to increase the mechanical properties of the ligament. The combined treatment of HA and collagenase did not positively affect the healing responses of the ligaments (including the MCL) and did not prevent adhesions within the connective tissue. A similar lack in preventing fiber adhesions in humans has also been reported [9].

In conclusion, our results indicate that administration of an NSAID and hyaluronic acid both induce positive effects on the healing responses and mechanical properties of MCL after injury. The response to the Diclofenac was better than the other interventions in the early stages of ligament recovery after injury. The fact that Control group did not have any surgery might indicate that comparison of normal healing is not possible. Thus, we should be more cautious on the effectiveness of Diclofenac in the MCL healing. Moreover, we are fully aware that the entire subject of MCL healing in animals model is quite complex. As such, despite our conclusions are valid we know that many other factors also influence healing thus a clinical correlation could be somewhat tenuous. Yet, the fact that the MCL specifically responded favorably to the Diclofenac treatment is additive to our knowledge.

## References

1. Almekinders L.C. (1990) The efficacy of nonsteroidal anti-inflammatory drugs in the treatment of ligament injuries. *Sports Med.* 9:137-142
2. Bancroft J.D., H.C.Cook (1994) In: *Manual of Histological Techniques and Their Diagnostic Application.* Churchill Livingstone, Edinburgh pp. 42-71
3. Bos P.K., J.De Groot, M.Budde, J.A.Verhaar, G.J.Osch (2002) Specific enzymatic treatment of bovine and human articular cartilage: implications for integrative cartilage repair. *Arthritis Rheum.* 46:976-985
4. Carlstedt C.A. (1987) Mechanical and chemical factors in tendon healing. Effects of indomethacin and surgery in the rabbit. *Acta Orthop.Scand.* (Suppl. 224):1-75



5. Carmeli E., A.Z.Reznick, R.Coleman, G.Volpin, N.Zarzhevsky (2001) Biochemical and histochemical study of hind limb muscles of aged rats after immobilization and re-mobilization. *Biol.Sport* 18:21-31
6. Dahners L.E., J.A.Gilbert, G.E.Lester et al. (1988) The effect of a nonsteroidal anti-inflammatory drug on the healing of ligaments. *Am.J.Sports Med.* 16:641-646
7. Dunham J., S.Hoedt-Schmidt, D.A.Kalbhen (1993) Prolonged effect of iodoacetate on articular cartilage and its modification by anti-rheumatic drugs. *Int.J.Exp.Pathol.* 74:283-289
8. Dvivedi S., S.M.Tiwari, A.Sharma (1997) Effect of ibuprofen and diclofenac sodium on experimental wound healing. *Indian J.Exp.Biol.* 35:1243-1245
9. Hagberg L. (1992) Exogenous hyaluronate as an adjunct in the prevention of adhesions after flexor tendon surgery: a controlled clinical trial. *J.Hand Surg.* 17:132-136
10. Hughston J.C. (1994) The importance of the posterior oblique ligament in repairs of acute tears of the medial ligaments in knees with and without an associated rupture of the anterior cruciate ligament: results of long-term follow-up. *J.Bone Joint Surg.* 76:1328-1344
11. Jokl P., N.Kaplan, P.Stovell, K.Keggi (1984) Non-operative treatment of severe injuries to the medial and anterior cruciate ligaments of the knee. *J.Bone Joint Surg.* 66:741-744
12. Kannus P., M.Jarvinen (1990) Non operative treatment of acute knee ligament injuries. A review with special reference to indications and methods. *Sports Med.* 9: 244-260
13. Miyasaka K.C., D.M.Daniel, M.L.Stone, P.Hirshman (1991) The incidence of knee ligament injuries in the general population. *Am.J.Knee Surg.* 4:3-8
14. Moorman C.T., U.Kukreti, D.C.Fenton, S.M.Belkoff (1999) The early effect of ibuprofen on the mechanical properties of healing medial collateral ligament. *Am.J.Sports Med.* 27:738-741
15. Muckle D.S. (1974) Comparative study of ibuprofen and aspirin in soft-tissue injuries. *Rheumatol.Rehabil.* 13:141-147
16. Nevo Z., D.Robinson, N.Halperin, Z.Yosipovitch (2000) Biological implants for connective tissue joint structures: cartilage, patella, menisci and ligaments. In: K.Sames (ed.) *Regenerative Medicine and Tissue Engineering*. Ecomed Verlagsgesellschaft AG & Co. KG pp. 1-32
17. Ohno K., A.S.Pomaybo, C.C.Schmidt, R.E.Levine, K.J.Ohland, S.L.Woo (1995) Healing of the medial collateral ligament after a combined medial collateral and anterior cruciate ligament injury and reconstruction of the anterior cruciate ligament: comparison of repair and nonrepair of medial collateral ligament tears in rabbits. *J.Orthop.Res.* 13: 442-449
18. Robins A.J., A.P.Newman, R.T.Burks (1993) Postoperative return of motion in anterior cruciate ligament and medial collateral ligament injuries. The effect of medial collateral ligament rupture location. *Am.J.Sports Med.* 21:20-25



19. Shelbourne K.D., D.A.Porter (1992) Anterior cruciate-medial collateral ligament injury: nonoperative management of medial collateral ligament tears with anterior cruciate ligament reconstruction. A preliminary report. *Am.J.Sports Med.* 20:283-286
20. Vogel H.G. (1977) Mechanical and chemical properties of various connective tissue organs in rats as influenced by non-steroidal antirheumatic drugs. *Connect Tissue Res.* 5:91-95
21. Wiig M.E., D.Amiel, J.VanderBerg, L.Kitabayashi, F.L.Harwood, K.E.Arfors (1990) The early effect of high molecular weight hyaluronan (hyaluronic acid) on anterior cruciate ligament healing: an experimental study in rabbits. *J.Orthop.Res.* 8:425-434
22. Woo S.L., M.A.Gomez, Y.Seguchi, C.M.Endo, W.H.Akeson (1983) Measurement of mechanical properties of ligament substance from a bone-ligament-bone preparation. *J.Orthop.Res.* 1:22-29
23. Woo S.L., S.S.Chan, T.Yamaji (1997) Biomechanics of knee ligament healing, repair and reconstruction. *J.Biomech.* 30:431-439
24. Woo S.L., C.Niyibizi, J.Matyas, K.Kavalkovich, C.Weaver-Green, R.J.Fox (1997) Medial collateral knee ligament healing. Combined medial collateral and anterior cruciate ligament injuries studied in rabbits. *Acta Orthop.Scand.* 68:142-148
25. Yamaji T., R.E.Levine, S.L.Woo, C.Niyibizi, K.W.Kavalkovich, C.M.Weaver-Green (1996) Medial collateral ligament healing one year after a concurrent medial collateral ligament and anterior cruciate ligament injury: an interdisciplinary study in rabbits. *J.Orthop.Res.* 14:223-227

Accepted for publication 29.12.2003

#### Acknowledgements

The study was supported by "The Anne and Eli Shapira Foundation", Portland, Oregon, USA

